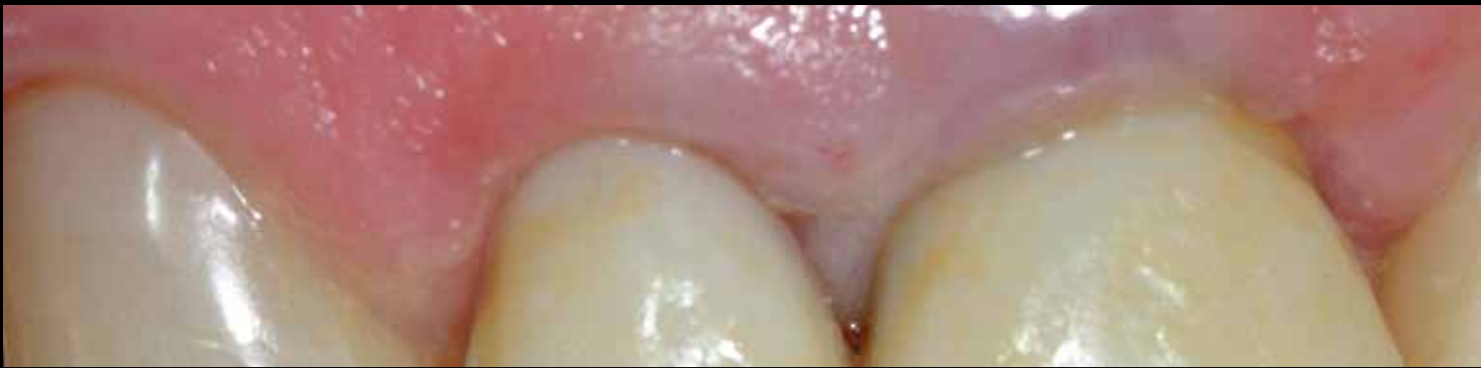
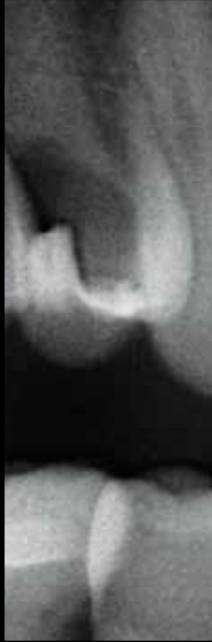
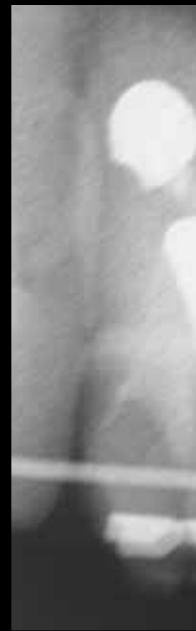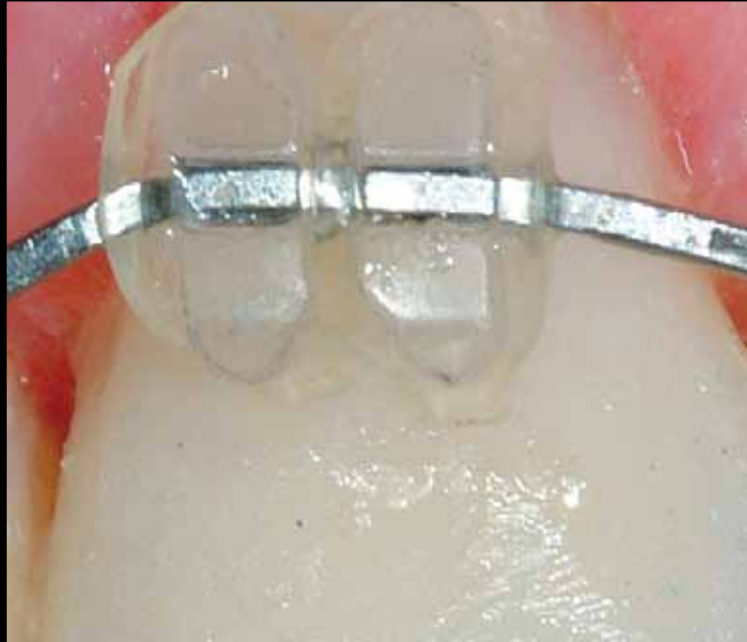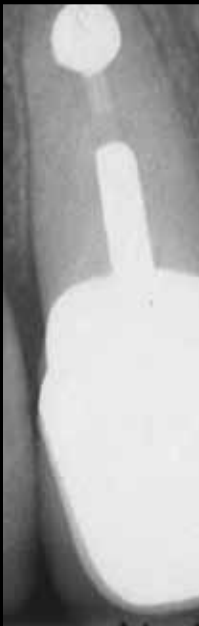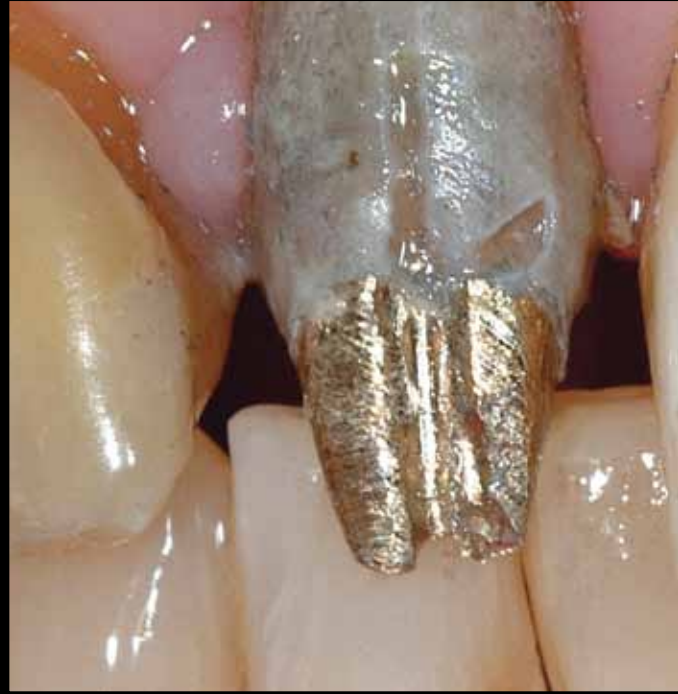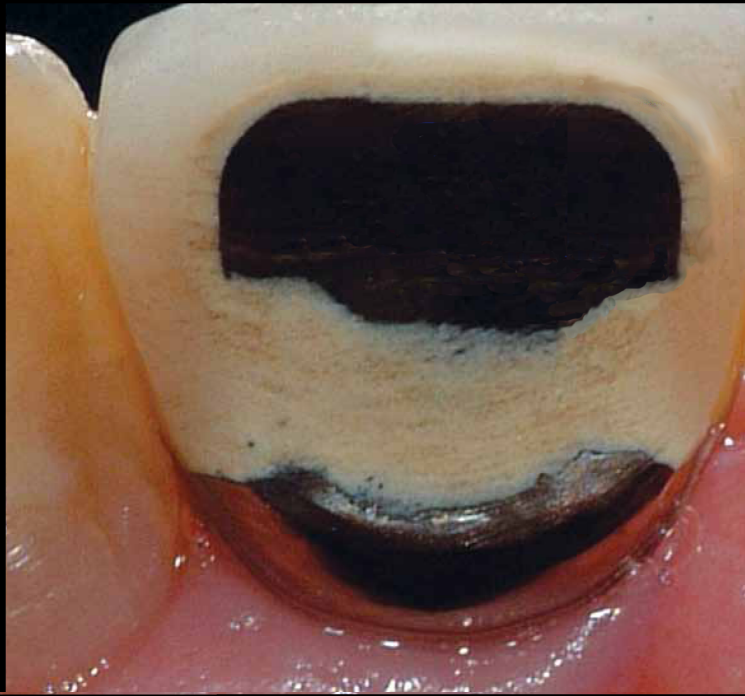ANTERIOR EXTRACTION & IMPLANT PLACEMENT IN A SEVERELY DEFICIENT SITE

Multidisciplinary Enhancement of Hard and Soft Tissue Profiles

Sergio Rubinstein, DDS
Maurice A. Salama, DMD
Henry Salama, DMD
David A. Garber, DMD
Mark B. Jacob, DDS



The digital version of this article features a webinar opportunity to learn more about this topic.

Abstract

Achieving optimal esthetic restorative results associated with anterior extraction and tooth replacement continues to be one of the most challenging endeavors in reconstructive cosmetic dentistry. When implant therapy is the treatment of choice, the margin for error is further decreased dramatically and methods to minimize and/or eliminate the potential for failure must be employed. This is especially relevant when the tooth to be extracted is associated with significant hard and soft tissue deficiencies. Assessing the patient's expectations, establishing a thorough diagnosis, and choosing the optimal therapeutic options to sequence and design treatment are key considerations for predictable success. Part 1 of this two-part article describes just such a clinical challenge related to the replacement of a severely compromised central incisor, with special emphasis placed on the utilization of pre-extraction orthodontic therapy to enhance the hard and soft tissue profile of the future implant receptor.

Learning Objectives:

After reading this article, the participant should be able to:

1. Understand the physiologic changes in soft tissue and bone that take place following tooth loss, and combine orthodontic and surgical techniques and treatment sequencing to help achieve predictable success.
2. Understand the benefits of monitoring the actual progress of treatment compared to the original treatment goals, as well as utilizing a team approach and multiple treatment modalities to obtain an ideal result.
3. Recognize the possible benefits of "hopeless" teeth in the ideal treatment sequence for an excellent outcome.



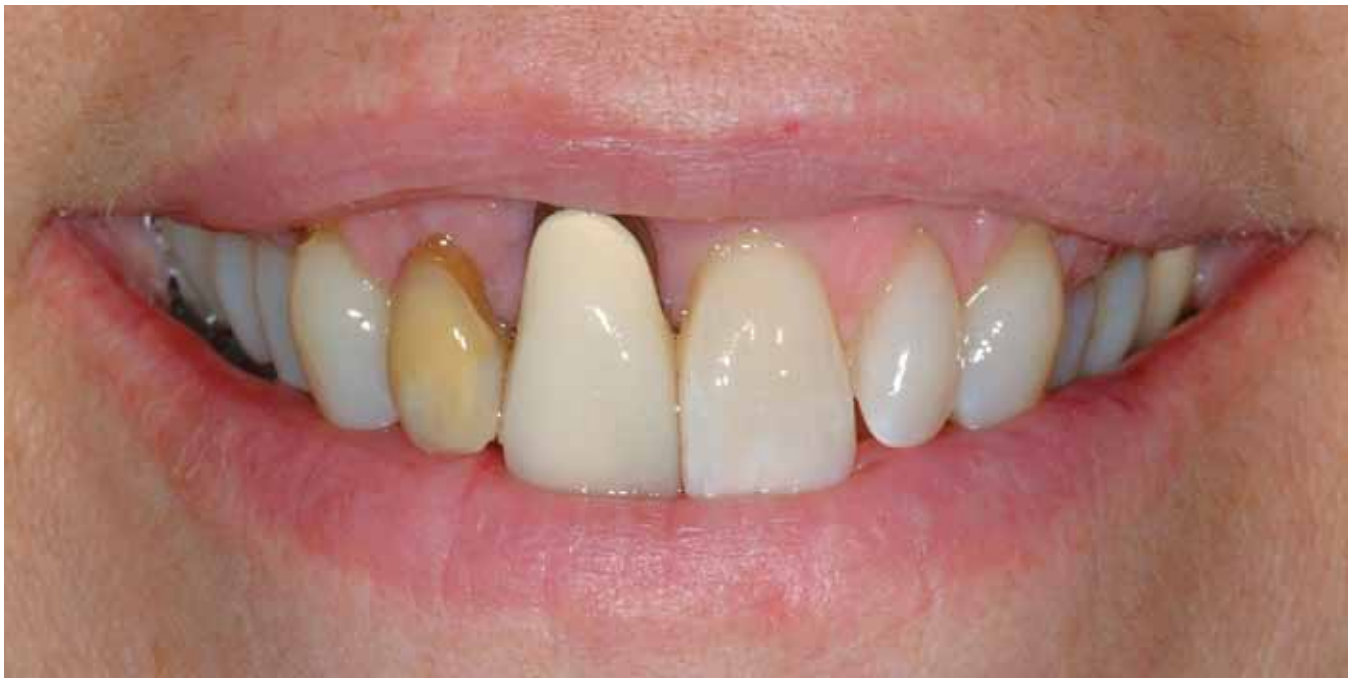

Figure 1: Image displaying the patient's high lip line. She also was unhappy with the cosmetic deformity related to her right central incisor.

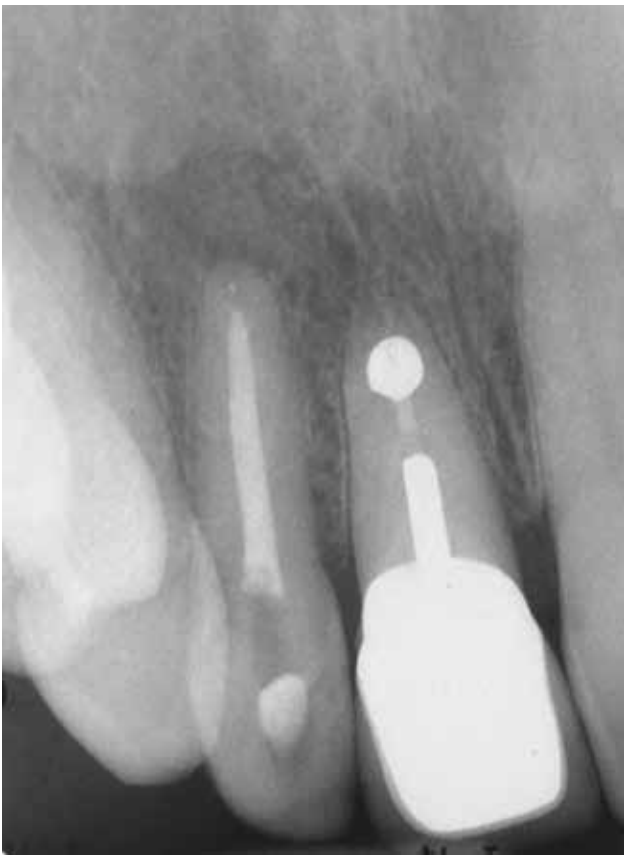

Figure 2: Periapical of #7 and #8.

Introduction

Extraction and implant placement is a functionally predictable therapeutic modality. Esthetic predictability, however, can sometimes prove elusive. This is especially true for the implant replacement of severely compromised anterior teeth with hard and soft tissue deficiencies within the esthetic zone. For the exacting patient facing such circumstances, it becomes incumbent on the clinician to recognize the challenge(s) through a thorough diagnostic protocol and thereafter to choose the optimal therapeutic options for overcoming them. With so many documented therapeutic options for techniques and materials available to clinicians today for reconstructing hard and soft tissue deficiencies, making optimal choices depends very much on the patient's expectations and the specific nature of the site being reconstructed.

This article highlights the decision-making process for the successful replacement of a hopeless maxillary central incisor exhibiting significant deficiencies in a challenging esthetic environment. In addition, special focus is placed on the benefits of utilizing pre-extraction adjunctive orthodontic eruption therapy to optimize the hard and soft tissue of the potential implant recipient site.

Clinical Case

A 57-year-old female presented with a non-contributory medical history except for oral bisphosphonate therapy over a five-year period. The bisphosphonate therapy was discontinued just prior to seeking a dental consultation. The patient's chief complaint at her first appointment was a significant concern about the existing right central incisor, particularly related to the considerable recession, exposed root, and associated cosmetic deformity (**Fig 1**).

An oral examination recorder generalized (+) mobility levels across her entire dentition except for the maxillary right central

In conjunction with the gingival recession and apicoectomy, the majority of the osseous labial plate of the right central incisor had resorbed.

incisor, which exhibited a Class II+ mobility. All posterior teeth presented with a balanced occlusion, a little localized recession, and a history of mild bone loss but were otherwise periodontally stable. The upper right lateral and central incisor had undergone endodontic therapy several years earlier, with the upper central incisor requiring a subsequent apicoectomy (Fig 2).

In conjunction with the gingival recession and apicoectomy, the majority of the osseous labial plate of the right central incisor had resorbed. While the defect on the labial of #8 was significant, it was also localized. Important influencing considerations were the anatomy of the soft tissue defect, having a triangular shape, as well as the lack of any attached gingivae (Fig 3).

Relevant Diagnostic Influences

Relevant diagnostic influences were as follows:

- high patient expectations
- high lip line
- gingival recession resulting in uneven gingival margins
- lack of attached gingivae, #8
- lack of labial plate of bone, #8
- lack of cosmetic smile parameters of balance, harmony, and continuity of form
- lack of shade match, #7.

Upon a thorough clinical evaluation, the lingual aspect of the crown showed aggressive occlusal adjustment on the porcelain and the metal substructure (Fig 4).

Discussion

The interdisciplinary team evaluated all possible treatment options for addressing the patient's chief complaint and enhancing the smile display. Principal among them were regaining balance, harmony, and continuity of form within the esthetic zone. A major concern was the expected position of the interproximal papillae around the central incisor with the anticipated treatment modalities.

To accomplish this goal, reconstruction of the lost bone and soft tissue in the area of the right central incisor is a primary consideration. Myriad surgical techniques are available today that are capable of accomplishing this. To correct such an extensive defect, however, all surgical protocols would require a staged approach of multiple procedures involving both bone

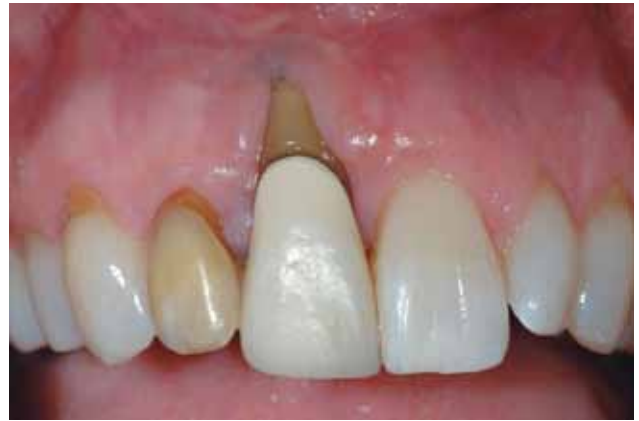

Figure 3: Advanced gum recession of 9 mm with loss of the labial bone. No attached gingivae, with the surrounding tissue extremely inflamed and exhibiting bleeding upon probing.

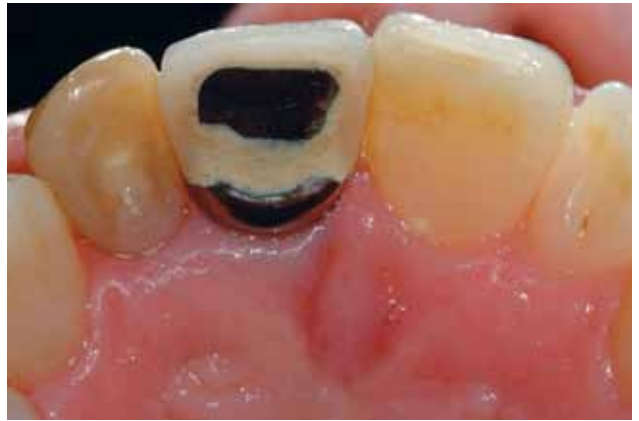

Figure 4: There was a history of aggressive occlusal adjustment on the #8 crown.

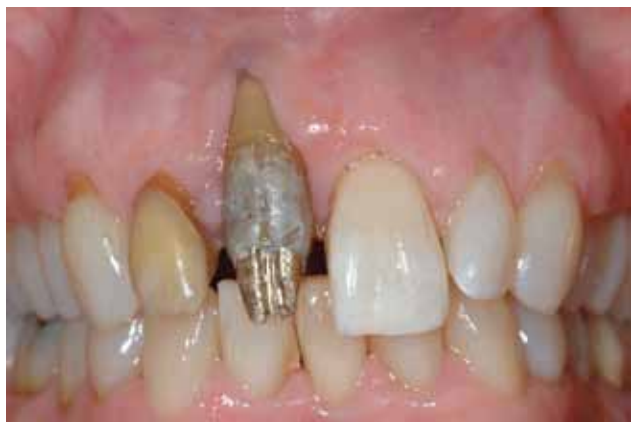

Figure 5a: Labial view of the right central incisor without the PFM crown.

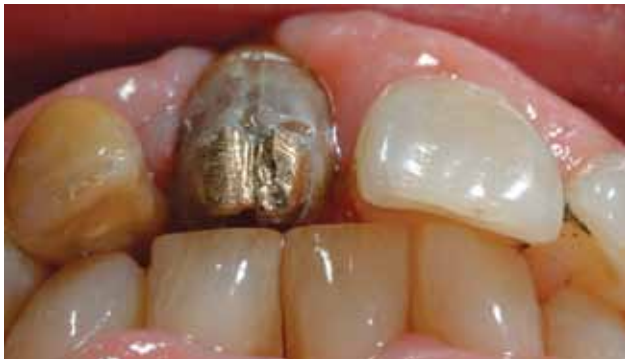

Figure 5b: Incisal view of teeth in occlusion. The gold post is touching the opposing incisor with no clearance for the final restoration.

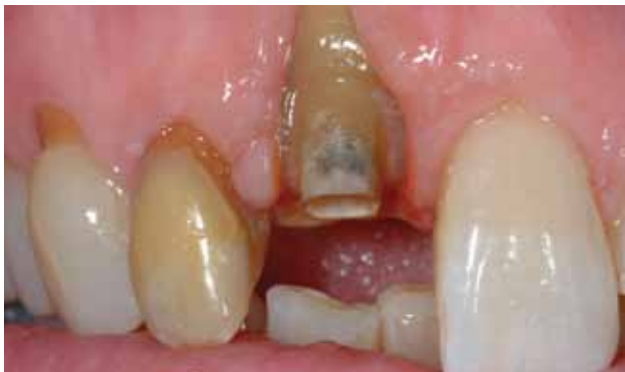

Figure 5c: Adequate incisal clearance must be created for the orthodontic eruption of the root to be accomplished in the absence of occlusal trauma.

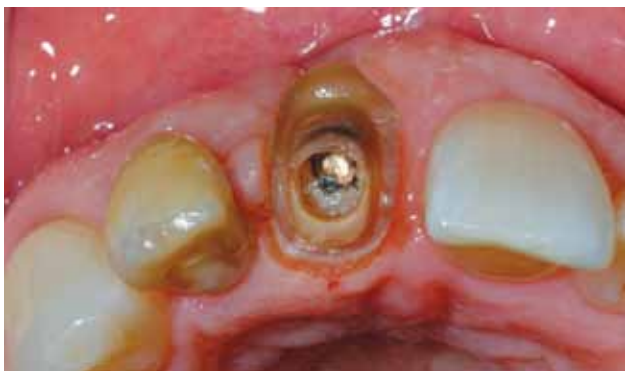

Figure 5d: Incisal view of the canal preparation, creating enough internal retention to prevent dislodgment of the provisional.

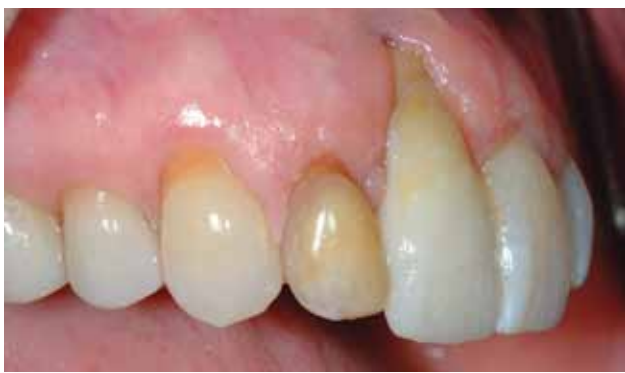

Figure 5e: Provisional restoration permanently cemented.

and soft tissue augmentation^{1,2} with subsequent corrective procedures often required. A patient with a recent five-year history of bisphosphonate therapy would need to be cautioned about such an aggressive approach if a suitable option presented itself. A possible alternative, adjunctive orthodontic eruption, is often considered when the hopeless tooth in question retains a relatively intact apical fiber apparatus capable of influencing the surrounding tissue. This orthodontic therapeutic modality is well documented and has been utilized effectively to help correct restorative, periodontal as well as esthetic clinical challenges.³⁻⁹

The literature also validates that orthodontic eruption stimulates bone deposition at the crest as the tooth migrates coronally. In addition, it has also been widely demonstrated that coronal soft tissue enhancement and an increase in keratinized gingivae can also be predictably accomplished utilizing orthodontic eruption.^{3,7,10} Therefore, whenever possible, the orthodontic solution is always considered right along with surgical options in the correction of hard and soft tissue defects. For this patient in particular, with a history of bisphosphonate therapy, it would also allow the team to more safely evaluate, along with appropriate blood tests, the clinical osseous response and metabolism prior to extraction or more involved surgical intervention such as bone and soft tissue grafting.

Sequence of Therapy

The porcelain-fused-to-metal (PFM) crown was removed to evaluate the remaining tooth structure, existing post, and tooth preparation (Fig 5a). An incisal view showed the tooth/post structure had no lingual/incisal clearance with the opposing dentition, possibly leading to active occlusal trauma¹¹⁻¹⁴ and the mobility pattern evident at initial examination (Fig 5b).

The lack of the lingual concave contour on the post did not allow for a proper anatomy on the final crown, which precluded the final restoration from functioning properly in a harmonic occlusal scheme either in centric occlusion or excursive movements. With caution, the post/tooth interface was opened with a thin diamond bur and, using an ultrasonic scaler, the post was removed and followed by significant tooth preparation to provide the necessary occlusal clearance of tooth/root structure. This allowed for enough clearance during orthodontic eruption (Fig 5c).

The intaglio of the canal was prepared as well to be a part of the provisional restoration and provide the required retention so that the temporary would not dislodge during orthodontic treatment. This retention was maximized by also permanently cementing it with a resin glass ionomer cement (Fig 5d).

Utilizing a transparent index from a study model and wax-up, a direct technique provisional was fabricated utilizing a bis-acryl composite material. The anatomy of the central incisor was reproduced to match the contour of the adjacent central incisor (Fig 5e).

Orthodontic Treatment

Any orthodontic intervention must be instituted only after inflammatory control has been accomplished. Therefore, oral hygiene instruction, scaling, and root-planing, as well as closed curettage, were performed prior to commencing orthodontic therapy. In addition, adequate retention is always necessary and often requires the inclusion of a minimum of two adjacent teeth, one on each side of the tooth being erupted, to be included in the mechanics deployed.

The orthodontic plan was to bring the root coronally and in a palatal direction to enable the adjacent soft tissue to cover the exposed root.^{3,7,10} Occlusal adjustment to create space with the opposing arch was implemented periodically and as needed, so that the tooth would not be under any undesirable occlusal load.

As the tooth was erupted, a narrower part of the root was brought coronally and diastemas appeared (Fig 6). Therefore, a direct composite facing was created over the existing provisional to reproduce again the full contour of the upper central incisor. New bracket was placed, again more gingivally, as orthodontic treatment had not been completed (Fig 7).

Following five weeks of the new orthodontic treatment, a periapical radiograph was taken to verify the progress and evaluate how much root still remained (Fig 8).

It was determined that orthodontic treatment was complete as the desired gingival architecture had been regenerated. At this point, the orthodontic mechanics were stabilized for three months to allow the tissue surrounding the erupted tooth to fully mature and mineralize prior to any surgical procedures (Fig 9).

After three months of splinting, the braces were removed, the remaining root fragment of the central incisor was extracted, and the lateral incisor previously endodontically treated was prepared for a new provisional supporting a cantilever central incisor. The gingival contour of the central incisor was purposely under-contoured to allow for a larger volume of soft tissue to mature around it. Having a normal gingival contour would tend to direct the healing soft tissue in a gingival direction and the intent was to create as much volume of soft tissue as possible (Fig 10).

To prevent any undesirable rotation of the provisional, it was cemented temporarily on the lateral incisor and a lingual wire was bonded to the adjacent central incisor (Fig 11).

Three months after extraction and temporization, a flap revealed adequate bone volume was created post-orthodontic eruption (Fig 12). However, given the demanding esthetic environment and the expectations of the patient, it was decided to over-engineer the case and further enhance labially utilizing a corti-cancellous autogenous graft in a staged approach (Fig 13).

After proper healing of the bone graft and allowing the soft tissue to mature (Fig 14), implant planning was done with the advantage of computerized tomography. Not only was the intent to plan for the best implant position in relation to an esthetic outcome, but also to measure the bone density after all implemented treatment modalities.

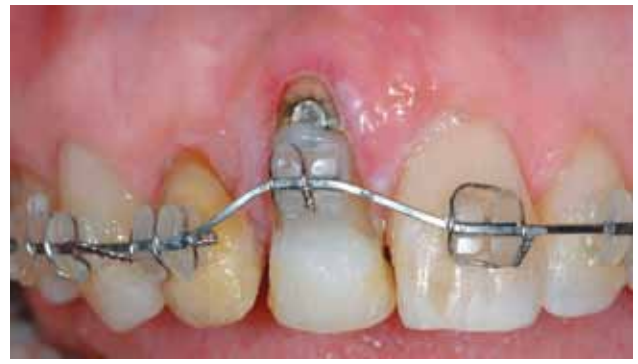

Figure 6: As the tooth is erupted, a narrower part of the root is brought coronally and diastemas appear.

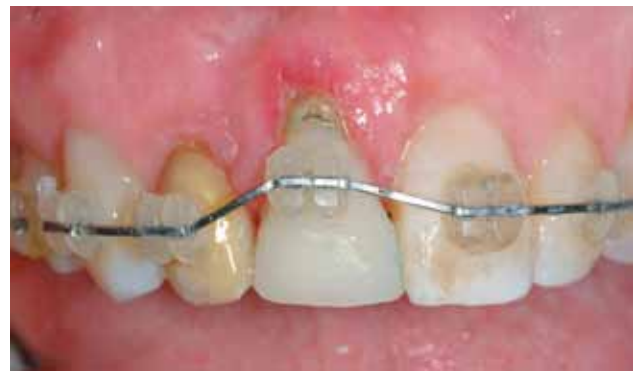

Figure 7: Modification of existing provisional to maintain original mesio-distal tooth width and form. Gingival tissues are rapidly adapting to the new tooth position.

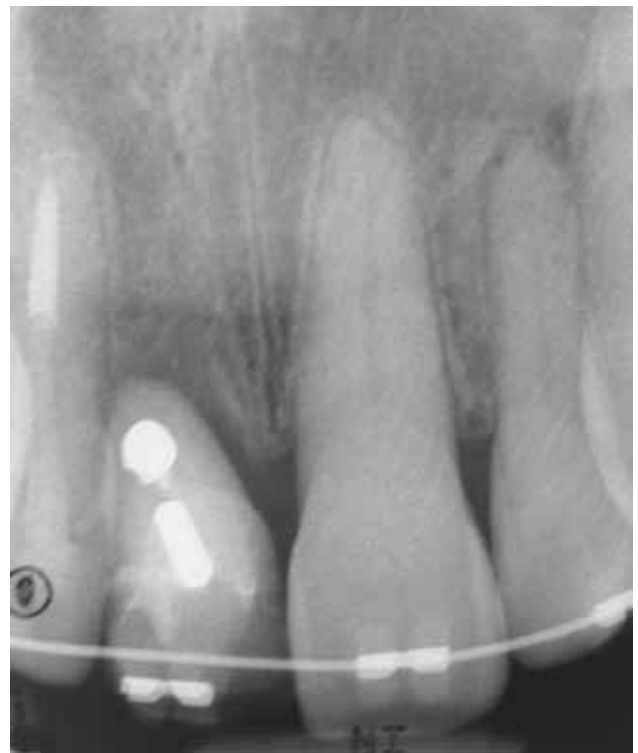

Figure 8: Radiograph after five weeks of orthodontic treatment.

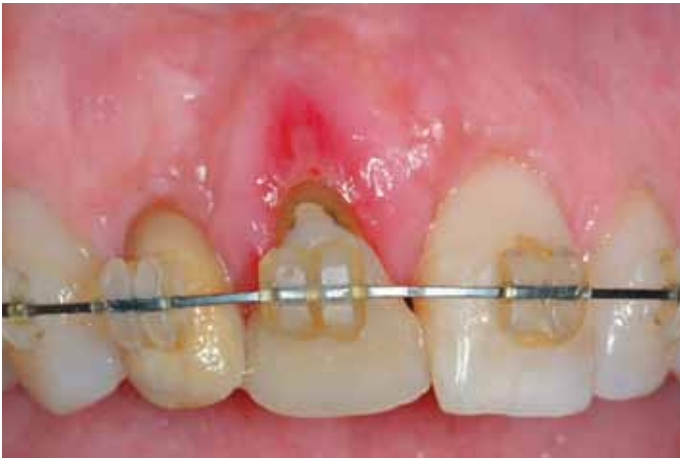

Figure 9: New orthodontic treatment completed in five weeks to meet the original objective of improving soft tissues and balancing gingival levels.

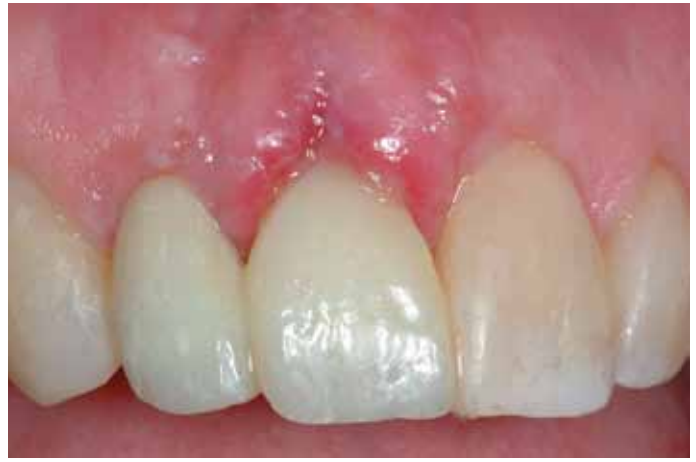

Figure 10: The #8 pontic using a subgingivally under-contoured provisional restoration splinted and cantilevered to the lateral incisor and bonded to the adjacent central incisor.

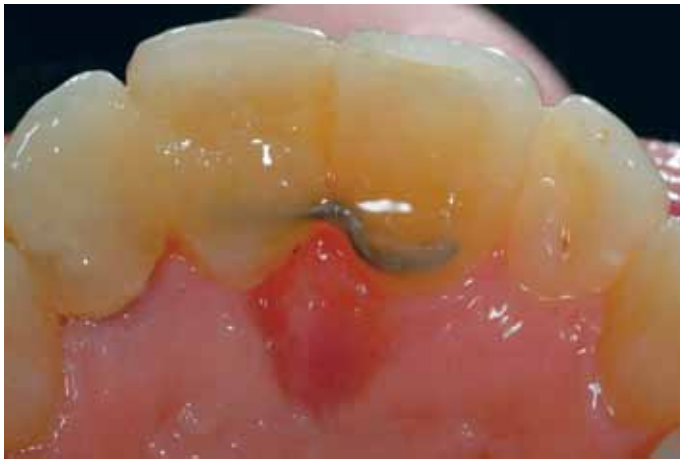

Figure 11: Lingual wire bonded to the adjacent central incisor to prevent rotation on the provisional.

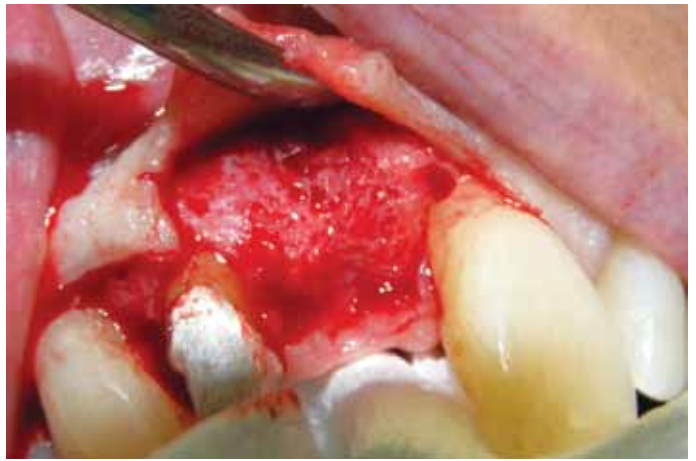


Figure 12: Bone profile post-orthodontic enhancement.

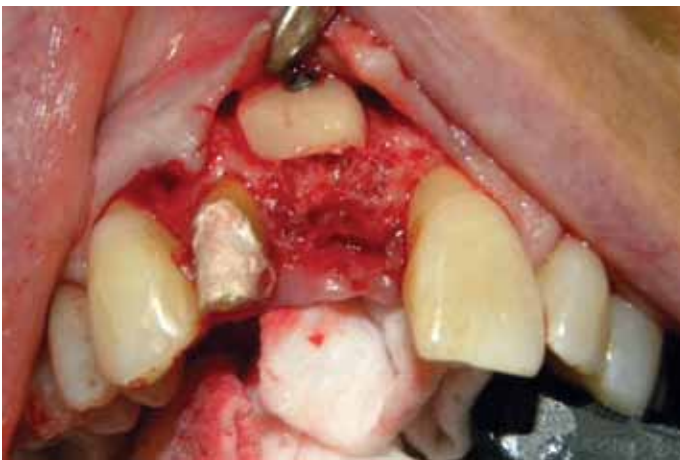

Figure 13: Bone graft in place, screw-retained for increased stability.

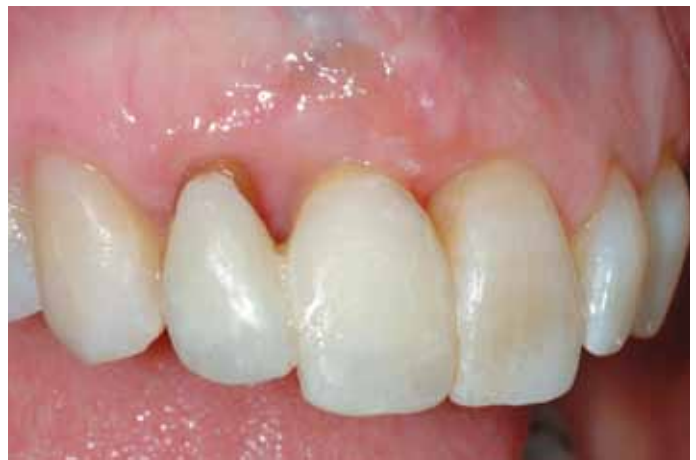

Figure 14: Provisional in place weeks after the healing of the bone graft.

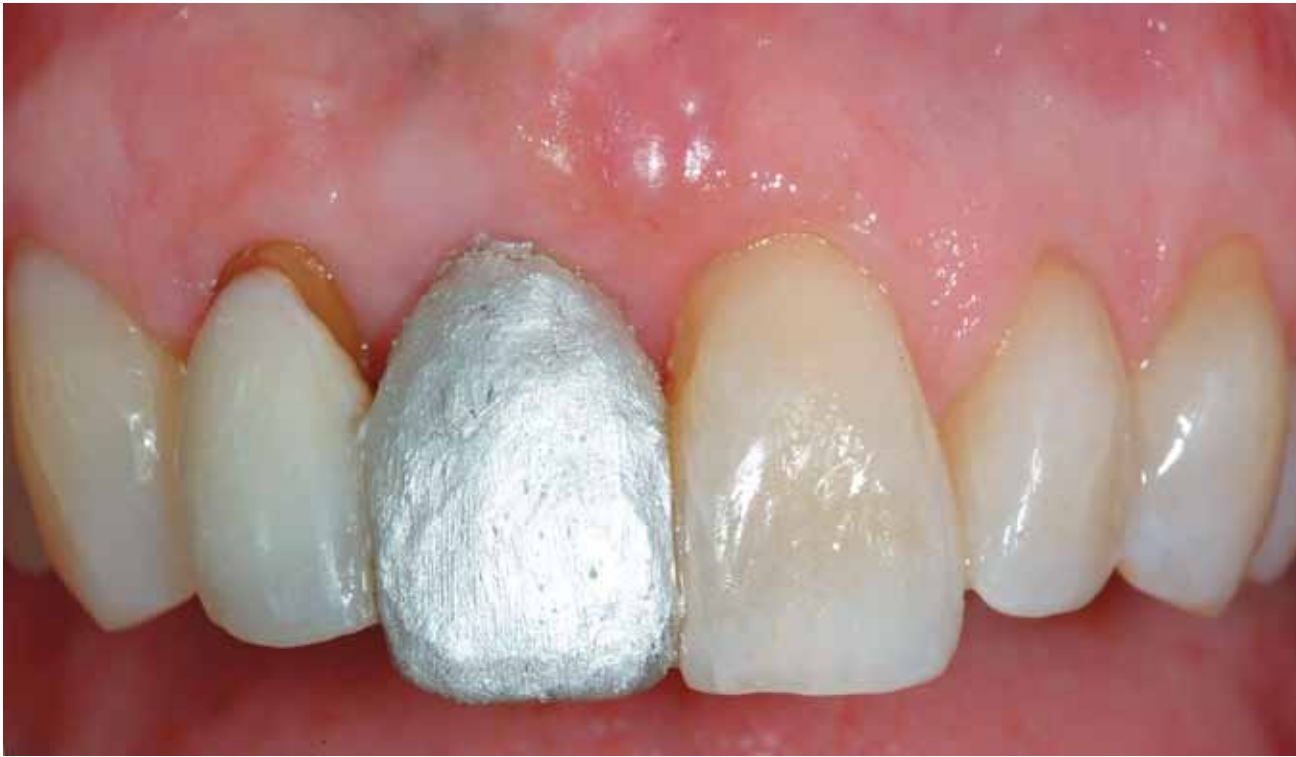

Figure 15: Colloidal silver painted over existing provisional to highlight tooth contours on the CT image.

After four months of healing, colloidal silver was painted on the provisional to have as a radiopaque reference of the outer contours of the provisional in relation to the available buccal-palatal bone. A computerized tomogram (CT) was taken to generate a digital planned surgery (Fig 15).

With the CT information, the implant type, size, width, and length were selected and placed in the best position to enable the projected final restoration to have a properly placed implant (Fig 16). A final impression was taken to create an accurate model to use for a computer-generated surgical guide.

Four months later the provisional was removed and the implant placed with the use of the computer-generated guide, which resembled the computerized planned position. The tissue was allowed to heal for six months^{1,2,8,9,15} (Fig 17).

Once it was determined the implant was osseointegrated, it was conservatively uncovered and a stock abutment was utilized to support a provisional (Figs 18a & 18b). It is important to let the soft tissue heal for several weeks and mature around the abutment. Once the proper soft tissue profile has been created around the implant-abutment-provisional restoration, a final impression can be taken in order to finalize the restoration in the laboratory.

Conclusion

Clearly, when a tooth has been lost or recently extracted and is associated with significant deficiencies, surgical reconstruction or restorative illusions are the only options remaining to clinicians. However, when a hopeless tooth still retains a critical degree of intact apical attachment apparatus, then “orthodontic

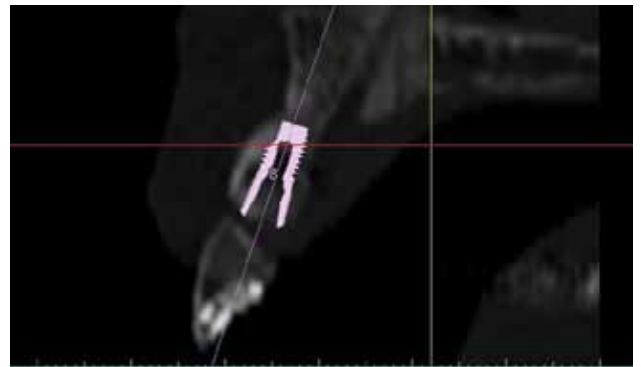


Figure 16: Computerized planning for best possible implant placement.

A major concern was the expected position of the interproximal papillae around the central incisor with the anticipated treatment modalities.

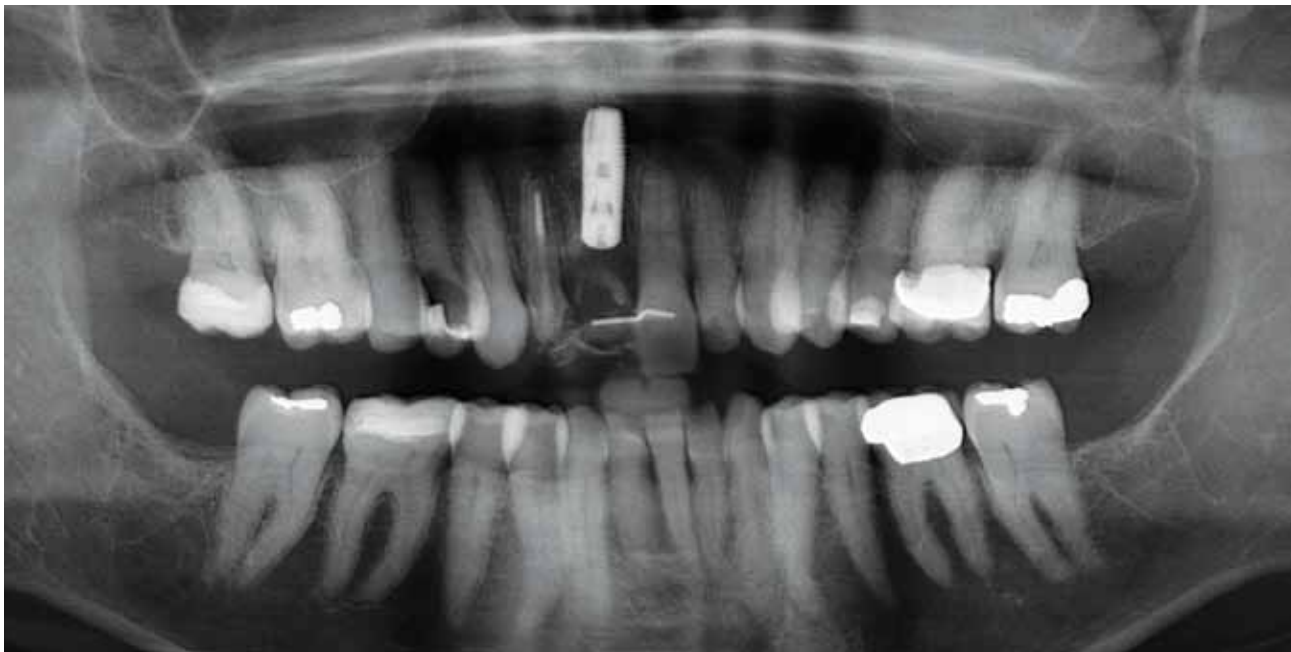

Figure 17: Periapical radiograph showing implant in position.

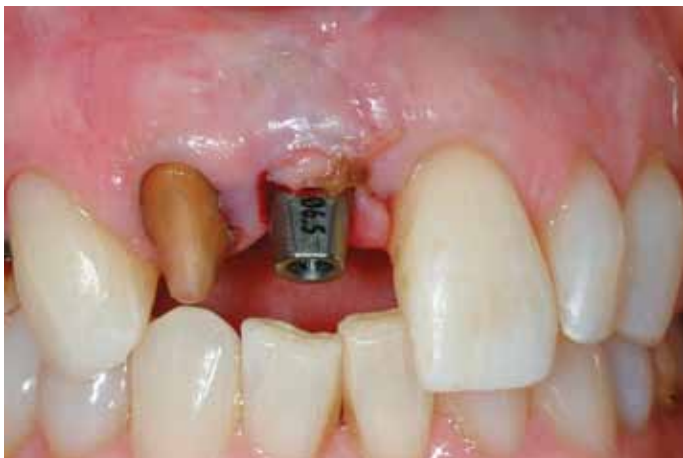

Figure 18a: Implant conservatively uncovered and stock abutment placed to support a provisional restoration.

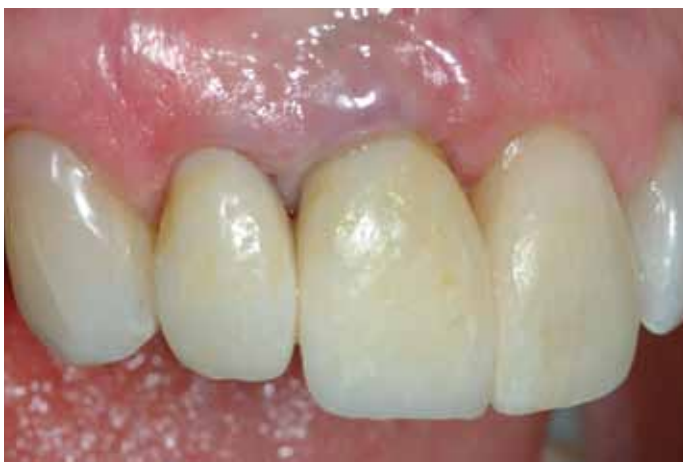

Figure 18b: Lateral and central incisors with provisional restorations.

extrusion” may be a viable modality to recreate lost hard and soft tissue profiles. This is especially true for patients that may require a cautious surgical approach. Therefore, we must revise our treatment design and make the necessary adjustments during therapy based on the implemented techniques, anticipated results, and host response. Mid-course evaluation can be critical and extremely helpful, even if a change of treatment modalities or sequencing is required. In the case discussed here, multiple treatment modalities—orthodontic, surgical, digital, and restorative—were utilized to regain balance, harmony, and continuity of form in a challenging esthetic environment.

Knowledge and experience can lead us to a proper decision-making process. Part 1 of this article described the diagnosis and tissue reconstructive phase of a severely deficient and hopeless central incisor. Through orthodontic enhancement of bone and soft tissue followed by surgical bone augmentation, an optimal foundation was established for an ideally positioned implant placement. In Part 2 of this article, the authors will describe the restorative and finalizing steps required to successfully follow through on the tissue reconstructive phase and achieve the desired esthetic result.

References

1. Touati B. Treatment planning for esthetic anterior single-tooth implants. In: R Romano, editor. *The art of treatment planning: dental and medical approaches to the face and smile*. London: Quintessence; 2009. p. 67-73.
2. Saadoun PA. Multifactorial parameters in peri-implant soft tissue management. In: R Romano, editor. *The art of treatment planning: dental and medical approaches to the face and smile*. London: Quintessence 2009. p. 77-153.
3. Salama H, Salama M. The role of orthodontic extrusive remodeling in the enhancement of soft and hard tissue profiles prior to implant placement: a

Knowledge and experience can lead us to a proper decision– making process.

systematic approach to the management of extraction site defects. *Int J Perio Rest Dent.* 1993 Aug;13(4):312-33.

4. Korayem M, Flores-Mir C, Nassar U, Olfert K. Implant site development by orthodontic extrusion: a systematic review. *Angle Orthod.* 2008 Jul;78(4):752-60.
5. Ghezzi C, Masiero S, Silvestri M, Rasperini G. Orthodontic treatment of periodontally involved teeth after tissue regeneration. *Int J Perio Rest Dent.* 2008 Dec;28(6):559-67.
6. Maeda S, Ono Y, Nakamura K, Kuwahara T. Molar uprighting with extrusion for implant site bone regeneration and improvement of the periodontal environment. *Int J Perio Rest Dent.* 2008 Aug;28(4):375-81.
7. Ogihara S, Marks MH. Enhancing the regenerative potential of guided tissue regeneration to treat an intrabony defect and adjacent ridge deformity by orthodontic extrusive force. *J Periodontol.* 2006 Dec;77(12):2093-100.
8. Rubinstein S, Nidetz A, Hoshi M. A multidisciplinary approach to single-tooth replacement. *QDT.* 2004;27:157-175.
9. Rubinstein S, Nidetz A, Heffez L, Toshi F. Prosthetic management of implants with different osseous levels. *QDT.* 2006;29:147-56.
10. Mantzikos T, Shamus I. Forced eruption and implant site development: Soft tissue response. *Am J Orthod Dentofac Orthoped.* 1997 Dec;112(6):596-606.
11. Ramfjord SP, Ash MM Jr. Significance of occlusion in the etiology and treatment of early, moderate and advanced periodontitis. *J. Periodontol.* 1981 Sep;52(9):511-7.
12. Ericsson I, Lindhe J. Lack of effect of trauma from occlusion on the recurrence of experimental periodontitis. *J. Clin Periodontol.* 1977 May;4(2):115-27.
13. Schluger S, Youdelis R, Page R, Johnson R. Occlusal traumatism as an etiologic factor. In: *Periodontal disease.* Philadelphia: Lea & Febiger; 1978. p. 107-132.
14. Poiate IA, de Vasconcellos AB, de Santana RB, Poiate E. Three-dimensional stress distribution in the human periodontal ligament in masticatory, para-functional, and trauma loads: finite element analysis. *J. Periodontol.* 2009 Nov;80(11):1859-67.
15. Schropp L, Isidor F, Kostopoulos L, Wenzel A. Optimizing anterior esthetic with immediate implant placement and single-implant treatment. *Int J Perio Rest Dent.* 1999;19(1):21-9. **JCD**



Dr. Rubinstein received his dental degree in 1980 and completed a specialty program in periodontal prosthetics at the University of Illinois College of Dentistry. He has a practice in Skokie, Illinois.

Dr. Maurice Salama is a visiting professor of periodontics at Nova University in Ft. Lauderdale, Florida, and a clinical assistant professor of periodontics at the Medical College of Georgia. He has a practice in Atlanta, Georgia.

Dr. Henry Salama is director of implant surgery at the University of Pennsylvania (UP) School of Dental Medicine. He also is a clinical assistant professor in the UP's Department of Restorative Dentistry. He has a practice in Atlanta, Georgia.

Dr. Garber is a clinical professor of oral rehabilitation and clinical professor of periodontics at the Medical College of Georgia. He also is a clinical professor in the department of prosthodontics at the University of Texas Health Science Center. He has a practice in Atlanta, Georgia.

Dr. Jacob is director of oral and maxillofacial surgery and facial trauma, and co-director of a general dental practice residency at NorthShore University HealthSystem in Highland Park, Illinois.

Disclosure: The authors have relationships with numerous manufacturers and have financial interest in most new developments in the science and art of dentistry over the past two decades. They did not report any disclosures specific to the content of this article.