

Endodontic-restorative symbioses: Diagnosis and treatment

← **11** page 1

Evaluation and diagnosis

With the technological evolution and predictability of osseointegrated dental implants, where does the endodontist's responsibility lie? With the different options available today, where does endodontic therapy stop and implants begin? When is that decision made? Who makes it? Several questions must be analyzed: is the endodontist's responsibility limited to only do an excellent root canal treatment? Should his role be also that of a gatekeeper and decision maker?

As treatment is initiated, many important questions will need answers:

- i) Does the available bone supporting the tooth warrant to proceed with endodontic treatment?
- ii) Is the tooth position and existing occlusion conducive to create a proper restoration?
- iii) Is there a craze or fracture line present?
- iv) Is there going to be a ferrule effect at the end of treatment?

Is the tooth going to need a post? And if so, will it accept a:

- a) Cast post? Or
- b) Direct technique due to canal configuration, tooth preservation and decreased likelihood of potential root fracture?
- c) Should root canal treatment be completed to allow for orthodontic supraeruption for prosthetic purposes or to improve the bone architecture even if the tooth is to be extracted? And finally,
- d) What is the material of choice to close the endodontic access at the end of therapy? (Figs. 1, 1a, 1b, 1c)

Case I

Intermediate restorative materials with eugenol can inhibit and prevent proper bonding techniques. Current glass ionomer restoration can provide a better seal; they are less susceptible to early occlusal breakdown and can provide a more stable interproximal contour. Just as essential is to communicate with the restorative dentist how the tooth is going to be rebuilt. Is the post going to be a cast post with a cemented technique or prefabricated post with

a bonded technique? A requisite of the post is to have an excellent and passive fit^{1,2,3,4} in the canal, and it is desirable if mechanical retentions are present for the core buildup stability, if a direct technique is utilized. Reality tells us these prefabricated posts sometimes need to be modified, therefore losing some of their inherent properties. The Peerless Post™ with its pre-stressed glass fibers allows for adjustments (shortening) to be made on either or both ends without sacrificing the fit or any of its physical properties or advantages (Fig. 1c).

Different practitioners feel comfortable with different post techniques. Some of the available post systems — such as SybronEndo-Peerless Post™, Coltene-Whaledent-Parapost™ and Bisco-DT-Light Post™, among others — have a post preparation bur that closely approximates the final shape of the post space, thereby ensuring a very close adaptation to the walls of the canals.

When analyzing post failures, we should understand the nature of the problem. Was the cast post improperly made yielding a non-passive fit? Could dislodgement be due to bonding failures as a result of the eugenol contained in some endodontic sealers such as Roth's sealer, Kerr Pulp Canal sealer and others? For the techniques that utilize resin-based cementation, an alternative sealer such as Ah2 or Resilon, a resin-based endodontic filling method may be indicated.

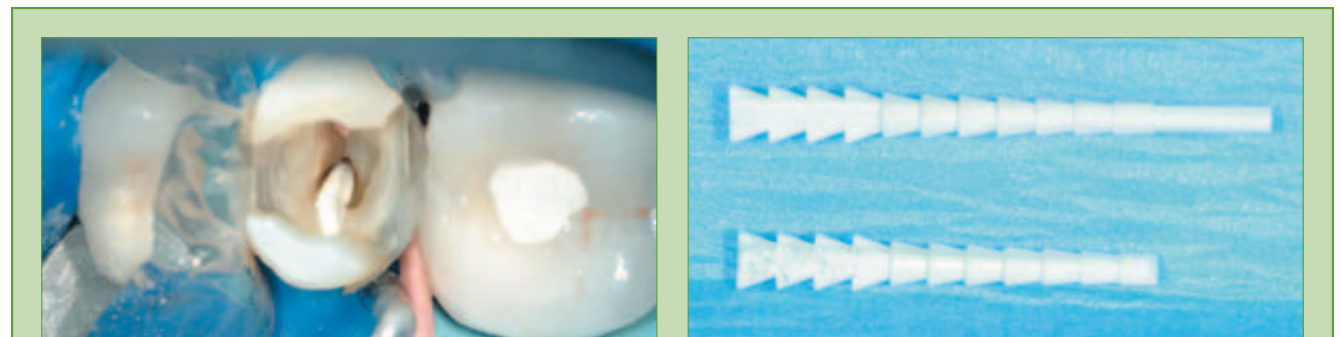
The final outcome as it relates to predictability and long-term success from the procedure must be visual-

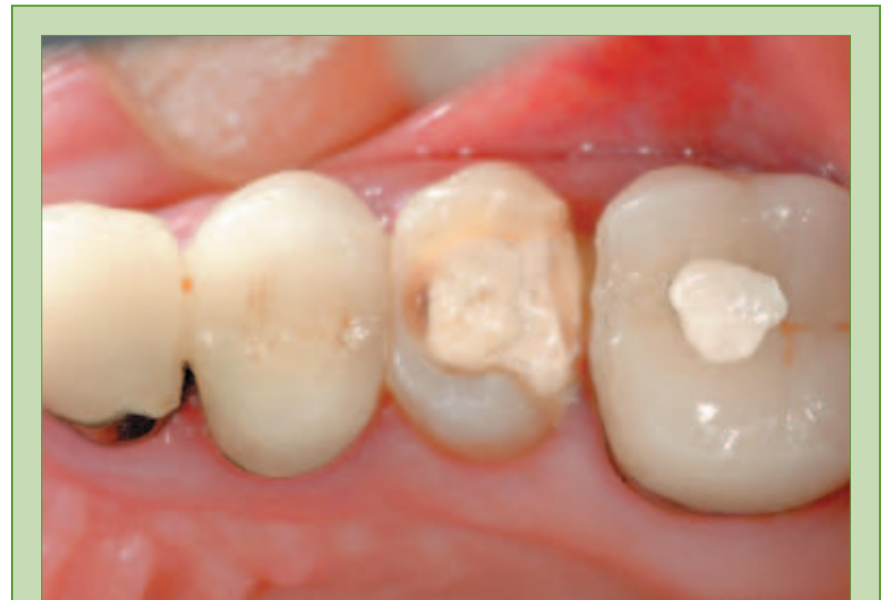

Fig. 1: Root canal completed with an intermediate restorative material. Note the gauging of the mesial wall of the molar crown.

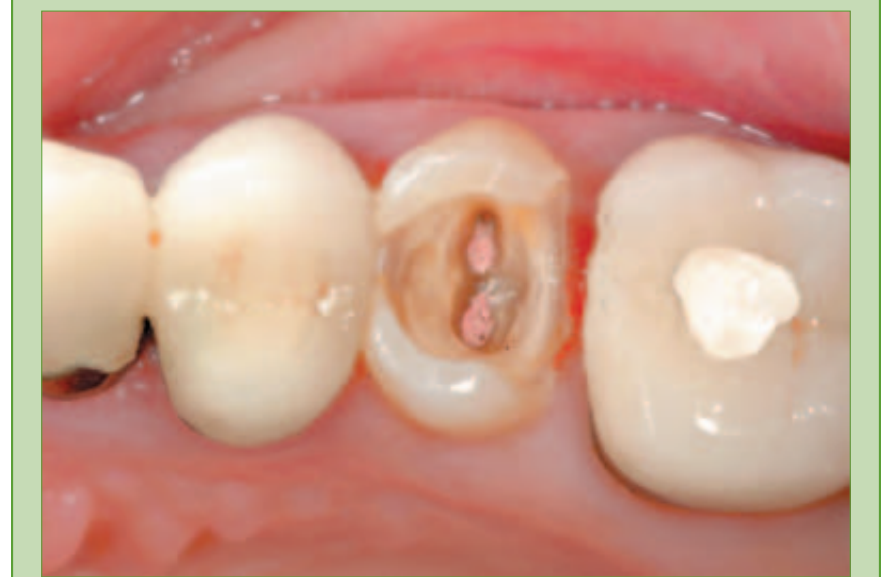

Fig. 1a: Occlusal view of endodontically treated tooth once the temporary material was removed. Having used an interproximal matrix could have prevented excess of material and gingival irritation.



Figs. 1b, 1c: Tooth isolated with properly adapted interproximal matrices to avoid gingival overhangs during the buildup. Tooth to be rebuilt with fifth generation bonding agent, self-cure resin cement and prefabricated post with mechanical undercuts and core buildup retentions.

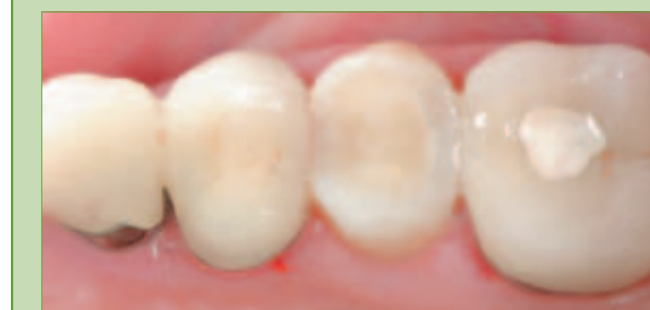

Fig. 1d: Upper second premolar rebuilt with a conservative prefabricated post composite buildup. The tooth is ready to be restored with a crown as well as replacing the adjacent crowns due to poor contours and marginal fit.

ized at the early stages of diagnosis, and with a favorable answer the treatment can be completed. The complexity lies when the previous mentioned concepts do not lead us to a clear and definite diagnosis and treatment plan or at the completion of treatment we feel the prognosis of the treated tooth is guarded.

Case II

On certain occasions, endodontic treatment or extraction followed by the placement of an implant are both available and should be presented to the patient. The questions are many, and the order in which they are asked will lead to: Are the teeth restorable? If so, can the endodontist provide a stable area, free of disease, upon which the restorative work will take place? Will the supporting periodontal tissues be preserved? It becomes necessary to take a heuristic approach to decision making in this type of cases.

When a tooth has been considered for extraction (Fig. 2), we question whether heroic treatments are still indicated, applicable and worthwhile.

Even though implants were an option at the time (in 1994), the overall understanding and comfort

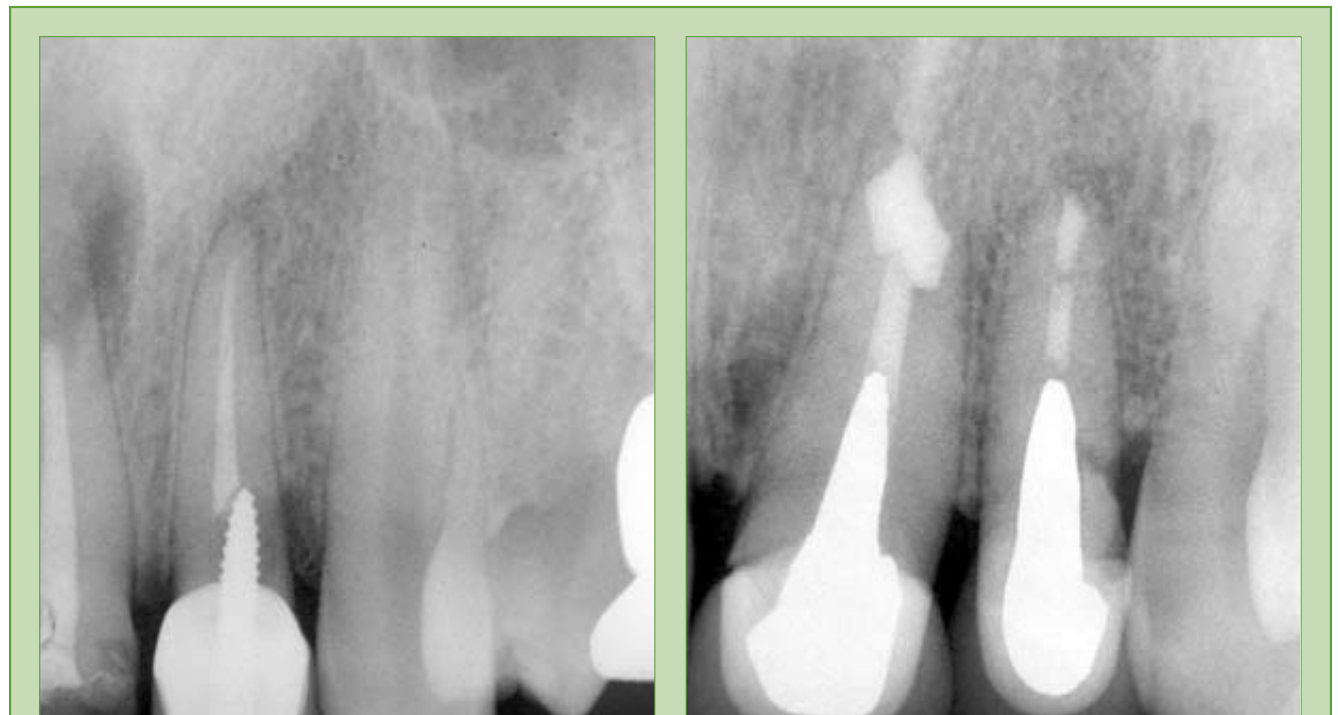


Fig. 2: Initial radiograph showing periapical pathology and tooth with guarded prognosis (1994).

Fig. 2a: Endodontic treatment completed and tooth restored with a cast post and core and a crown (1994). Root canal treatment by Paul Bery D.D.S.

level of replacing a single tooth was still evolving in the areas of implant design, abutments and soft tissue management. With this information at hand, the patient was keen on saving his teeth. Cases like this represent an enormous challenge, because they require a multidisciplinary

approach and a high degree of operative and laboratory skill in order to obtain biological and esthetically sound results. The patient presented with both teeth filled with a nonsoluble paste. Endodontic retreatment was performed first, to alleviate symptoms and to at-

tempt to determine the available remaining root structure from a restorative point of view. When the resorptive defect was noted on the upper left central, apicoectomies

→ ET page 10

AD



A CALL TO ACTION!

...because every child deserves a healthy smile



As dental industry participants and providers, we can all stand united in the fight to eliminate the #1 chronic childhood disease in the nation: pediatric dental disease.

An estimated 4 to 5 million children in the US experience dental pain so severe it impairs their ability to eat, sleep and learn. These children have the least financial resources and are usually last to receive the oral health care they so critically need. Sadly, recent newspaper headlines have brought attention to the fact that some of these children are literally dying due to lack of access to proper care.

The National Children's Oral Health Foundation's (NCOHF) sole mission is to provide direct access to preventive education and treatment for our nation's youngest and most vulnerable citizens. With community-based programs that deliver the best approaches to eliminate dental disease, NCOHF is aggressively responding to the cries for help.

We are proud to announce the NCOHF Toothfairy Project, a national campaign to provide the financial support and deliver the care desperately needed to America's children. This tremendous and unprecedented undertaking requires significant funding. We are asking everyone connected to the dental industry to make a financial pledge within the next two months. Universal support is needed to show the critical nature of this national health problem.

The five of us have chosen to contribute our corporate dollars and assume leadership roles on the founding NCOHF Board of Directors. We sincerely believe that the National Children's Oral Health Foundation is making a historic change in the way we care for our nation's at-risk children. This effort has already

united some of the leading clinicians, researchers, corporations, universities, and professional organizations to ensure the establishment of the finest network of exemplary non-profit pediatric oral health care facilities.

Immediate action must be taken to transform children's pain and hopelessness into healthy smiles and bright, productive futures.

Please make your commitment today! Visit www.ncohf.org or call 1-800-350-1600.


Dan Even
President
Sybron Dental Specialties



Scott Anderson
President
Patterson Dental Supply



Tom Engels
Vice President
3M ESPE



Chris Clark
EVP & COO
DENTSPLY



Robert Hayman
CEO
Discus Dental



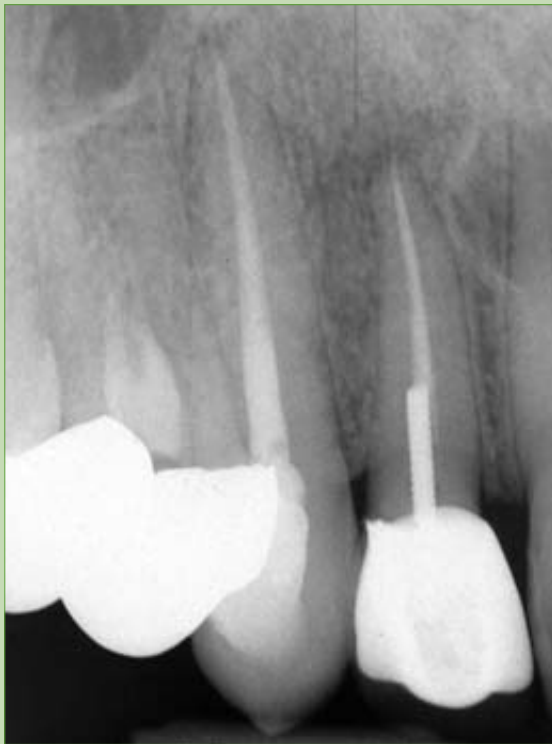

Fig. 3: Initial radiograph of root canal recently completed (1995).

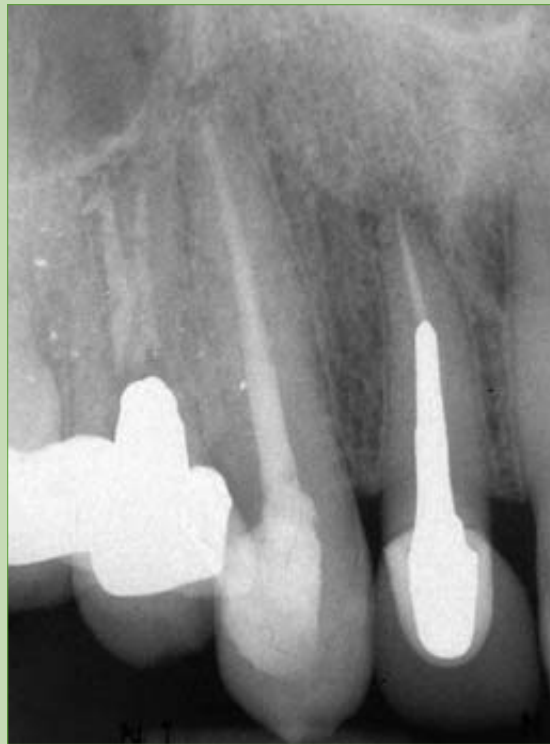

Fig. 3a: Post and core and crown showing periapical radiolucency 11 years later (2006).

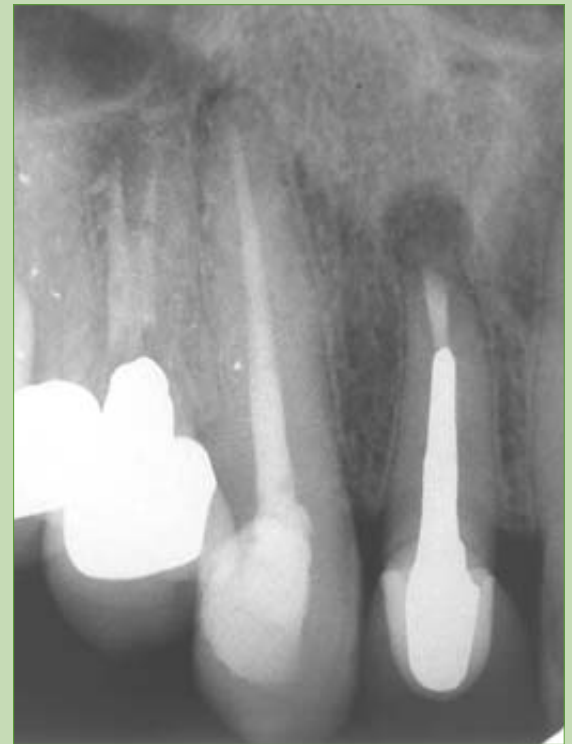

Fig. 3b: Radiograph of upper right lateral with apicoectomy.

← **ET** page 9

were performed on both teeth. Once periodontal stability was created and the periapical lesions eliminated, cast posts were made due to the canal size and coronal destruction, followed by porcelain crowns (Fig. 2a). After functioning for 12 years and due to a subgingival fracture of the root, the lateral was lost a year after the X-ray was taken. Careful evaluation of the occlusal patterns of this case permitted the patient to enjoy the use of his natural teeth, while at the same time preserving the crestal bone, as can be appreciated from the before and after radiographs.

Case III

On the same patient, the contralateral side (upper right lateral) also presented unique challenges (Fig. 3). Although the coronal structure had been preserved to a larger degree than the other upper lateral, the patient presented at a later date with the loosening of the original post and crown. As the endodontic therapy had been performed recently, it was decided to only redo the post and core and crown (Figs. 3a, 3b). While the results were initially favorable, the root canal therapy failed eventually, necessitating an apicoectomy (Fig. 3c). In this instance, it is evident that the original endodontic treatment should have been retreated. It has been shown that endodontically treated teeth exposed to the oral cavity will exhibit contamination of the root system in a relatively short period of time^{5,6}. Thus, by the time the patient presented himself with the problem, the canal had been exposed to then oral environment for several days,

jeopardizing the long-term success of the endodontic treatment. This was evident upon the failure of the treatment, necessitating surgery in order to resolve the problem. The surgery was uneventful, allowing the patient to retain the upper right lateral for 11 more years. In retrospect, the loss of this tooth was due not to the endodontic treatment but to the difficulty in properly restoring a tooth with significant loss of the coronal structure.

The ability and opportunity to allow for materials and techniques to improve over the years without compromising the patient's long-term care can prove in some instances to be invaluable, especially if an irreversible procedure is recommended, such as an extraction and the placement of an implant. Sometimes, even with a poor prognosis, it is important to preserve a tooth if only for a relatively short period of time in order to perform orthodontic supraeruption.

It is for this reason that an interdisciplinary approach can dictate optimum treatment from the onset. Patients are hesitant to invest in a root canal treatment for a tooth that could be extracted shortly. If a root canal is already present in the involved tooth, patients may accept orthodontic treatment more easily (Fig. 3d). Root canal treatment prior to the supraeruption procedure will eliminate any discomfort associated with the incisal or occlusal reduction of the tooth and its proximity to the pulp tissue. If supraeruption is to be implemented and root canal therapy is not in place, the patient's comfort could be at risk during this phase of treatment.

Once the extraction is completed, the expected result is to have bone and soft tissue remodeling. This nat-

ural response in the anterior region becomes more critical, because the papillae(s) will be lost. With the attempt to preserve crestal bone, osseous grafting is not only indicated but needed. However this procedure will normally result in some shrink-

age in a buccal lingual and coronal direction. By supraerupting the tooth, bone and soft tissue migration will occur in an incisal or occlusal

→ **ET** page 12

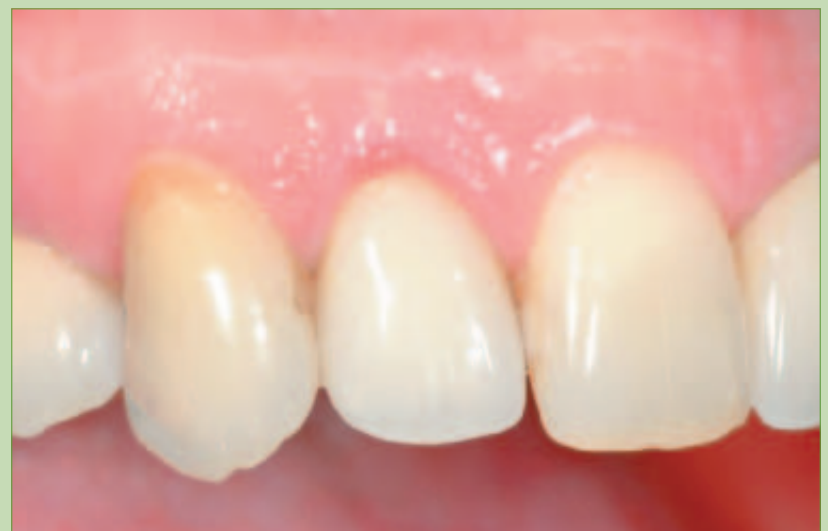

Fig. 3c: Crown on upper right lateral in place for 11 years before requiring its extraction due to subgingival fracture (note height of gingival margin).

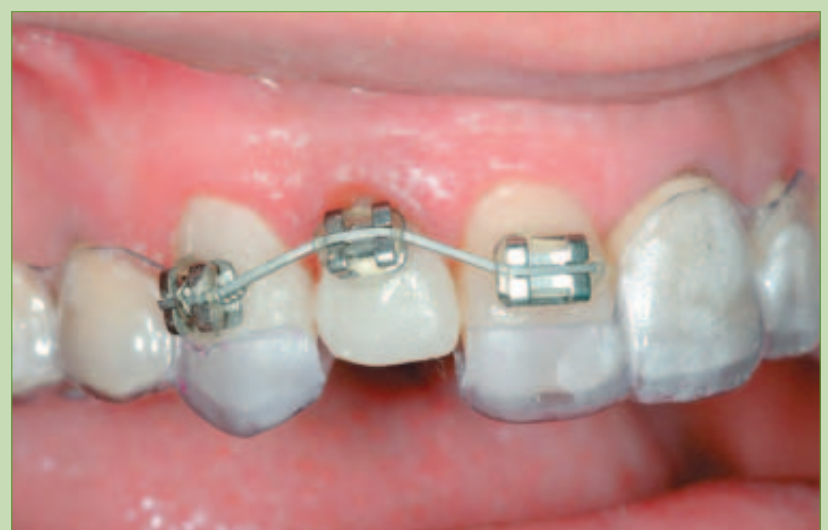

Fig. 3d: Tooth over reduced incisally with provisional in place to supraerupt hopeless tooth.

← **ET** page 10

direction^{7,8} (Fig. 3e), and by overcorrecting these landmarks when the tooth is extracted the soft tissue and bone should shrink to a normal gingival height. Then the options will be to immediately place the implant or do minimal bone grafting. As a consequence of improving the bone and soft tissue bed, the implant can be placed in an optimum location (Figs. 3f, 3g).

The combination of the supraeruption, proper surgical technique, provisionalization and completion of the implant supported crown with the appropriate contours will minimize or eliminate undesirable gingival embrasures, thus obtaining a more esthetic result. Final esthetics will depend on having the correct porcelain shade, value, texture and contours to maintain soft tissue health and support (Fig. 3h).

Conclusion

There is no question that with changes in clinical philosophies and approaches, the roles of the general practitioner and the specialist are being redefined. The introduction and upwardly spiraling popularity of dental implants has necessitated a change in the clinical approach to saving and restoring teeth. Heroic endodontic treatments on teeth are becoming less frequent and less necessary, because in many instances a more predictable result can be obtained by the use of a dental implant. Because of the availability of alternative techniques, it has become imperative that good prognostic values are obtained during the treatment plan phase.

Modern endodontic technology permits the clinician to make decisions based on sound findings and not on guesswork or empirical beliefs. Endodontists are better prepared to perform retreatment. At the same time, it has become necessary to learn to evaluate those retreatments before definitive work is per-

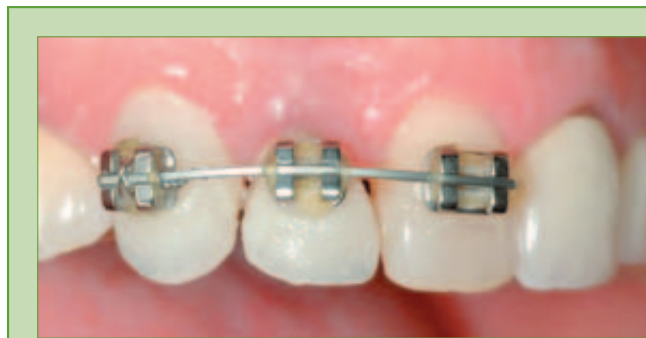


Fig. 3e: Orthodontic supraeruption completed in order to bring down the bone and soft tissues.

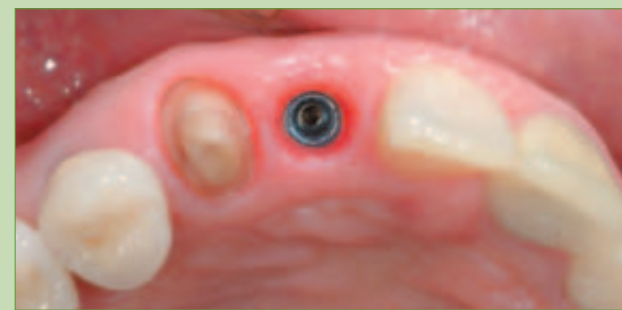

Fig. 3f: Incisal view showing implant position and excellent tissue response. Implant placed by Robert Bressman D.D.S., M.S. (Periodontist, Skokie, Ill.)

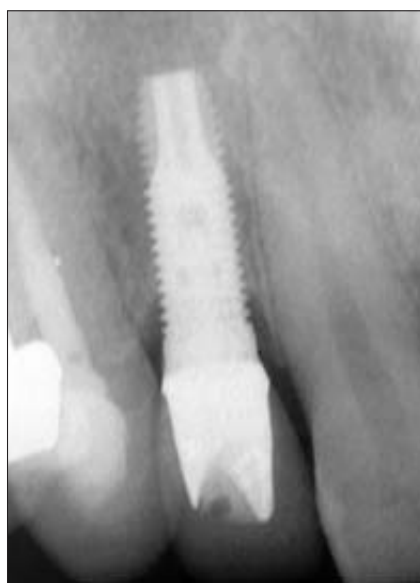

Fig. 3g: Radiograph of implant and final restoration.

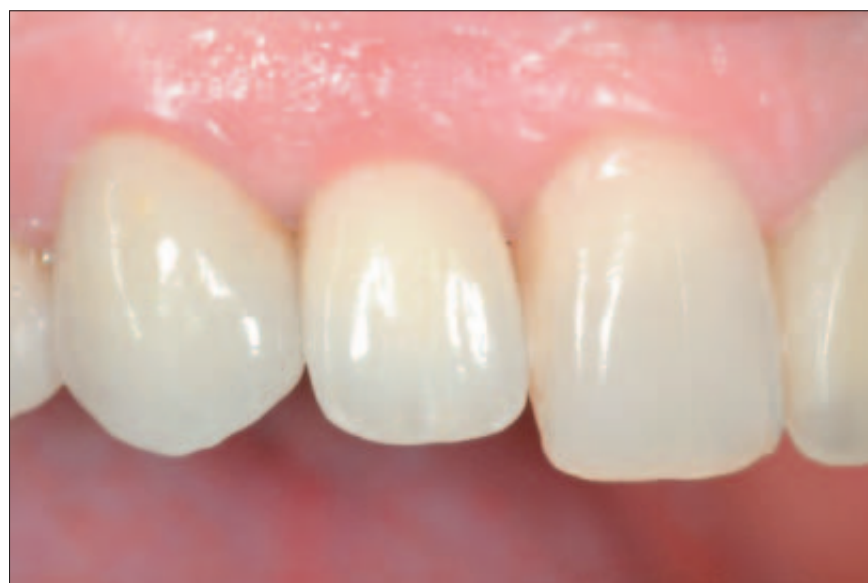


Fig. 3h: Final crown implant supported with proper tissue contours and papillae preservation. Laboratory work by Fujiki Toshi RDT, Skokie, Ill.

formed. The presence of altered internal anatomy, or the inability to fully instrument and clean the canal to its apical terminus are two important conditions that, when encountered, may require re-evaluation of the treatment plan, or at least a more prolonged period of observation to assess healing.

In this time of very sophisticated technological and scientific advances, it has become more important than ever that a careful and well-thought communication exists between practitioner, specialist and patient, in order not only to provide the best available treatment but also to give the patient realistic expectations on the decisions that he will be required to make. **ET**

References

- Gomes J.C., Cavina D.A., Gomes O.M., Neto J.P., Romanini J.C., Uso dos pino intrarradiculares adesivos nao metalicos, Revista Academia Brasileira De Odontologia 1999.
- Kogan E., Postes flexibles de fibra de vidrio (tecnica directa) para restauracion de dientes tratados endodonticamente, R. Asoc. Dent. Mex. Ene Feb 2001.
- Fernandes A., Shetty Sh., Coutinho I., Factors determining post selection: A literature review, J Prosth. Dent. Dec 2005.
- Christensen G., Post concepts are changing, JADA Sep 2004.
- Torabinejad M., et al: In vitro bacterial penetration of coronally unsealed endodontically treated teeth, JOE 16:566, 1990.
- Lazarsky et al: Epidemiological evaluation of the outcomes of nonsurgical endodontic therapy in a large cohort of insured dental patients, JOE 27:791, 2001.
- Salama H., Salama M., The role of orthodontic extrusive remodeling in the enhancement of soft and hard tissue profiles prior to implant placement: A systematic approach to the management of extraction site defects, Int J Periodont Rest Dent 1995;13(4):312-333.
- Rubinstein S., Nidetz A., Hoshi M., A Multidisciplinary Approach to Single-Tooth Replacement, QDT 2004; 157-175.

ET About the authors



Dr. Sergio Rubinstein received his dental degree in 1980 from the Universidad Tecnologica de Mexico. From 1980 to 1982 he completed his specialty training in Periodontal-Prosthesis at the University of Illinois at Chicago, where he was an assistant professor until 1992. He is the co-inventor of a custom abutment to prosthetically correct misaligned implants. He has lectured nationally and internationally, and he has published several articles in Adhesive Dentistry and Implant-Prosthodontics.

Dr. Rubinstein can be reached at:

Oral Rehabilitation Center
64 Old Orchard Road, Suite 420
Skokie, IL 60077
Phone: 847.673.9292
Fax: 847.674.4696



Dr. Paul Bery received his D.D.S. from the Technological University of Mexico in 1980. In 1985, he received his Certificate in Endodontics from the University of Illinois, where he was an assistant professor for several years. He is the author of several endodontic articles, and he has lectured both in the United States and abroad, particularly in South America. He presently is in private practice in Evanston, Ill.

Dr. Bery can be reached at:

636 Church St., Suite 517
Evanston IL 60201
Phone: 847.475.0120
Fax: 847.475.7885
Email: pfbery@msn.com